

# Endometriosis in Postmenopausal Woman Without Previous Hormonal Therapy: A Case Report

Mine İSLİMYE TAŞKIN<sup>1</sup>, Meltem ÇAĞRI MENTEŞE<sup>1</sup>, Engin UZGÖREN<sup>2</sup>, Ümit İNCEBOZ<sup>1</sup>

Balıkesir, Turkey

## ABSTRACT

Endometriosis is a benign, estrogen-dependent, chronic gynecological disorder commonly associated with pelvic pain and infertility. The prevalence of pelvic endometriosis is high, affecting approximately 6-10% of women of reproductive age. Although endometriosis has been associated with the occurrence of menstrual cycles, it may affect between 2-5% of postmenopausal women. In this presentation, we would like to draw attention to such cases of postmenopausal endometriosis.

A 56-year-old woman was presented with postmenopausal vaginal bleeding. Her menopausal status occurred at 46 years of age. She had neither personal history of endometriosis and a prior history of pelvic pain nor previous hormone use. A pelvic ultrasound scan revealed a right ovarian cystic mass of approximately 2.6x2.1cm in size and a left ovarian multiple lobated hemorrhagic cystic mass approximately 5.0x2.8 cm in size. Cancer antigen 25 (CA 125) level appeared to be within the normal range. The patient was then submitted to a computed tomography scan that showed multiple lobated cystic masses at both adnexa. Total abdominal hysterectomy and bilateral salpingoophorectomy was performed. The histological analysis confirmed an ovarian endometriotic cyst.

Endometriosis may be found in postmenopausal women, even without a history of previous hormone use. Thus, endometriosis should be considered in the differential diagnosis of postmenopausal adnexal masses.

**Keywords:** Menopause, Endometriosis, Ovarian cyst

Gynecol Obstet Reprod Med 2015;21:158-160

## Introduction

Endometriosis is a common, benign, chronic gynecological disorder commonly associated with pelvic pain and infertility. It is believed that estrogen is the major promoter of endometriosis growth.<sup>1</sup> The prevalence of pelvic endometriosis is approximately 6% to 10% of women of reproductive age. Although endometriosis has been associated with the presence of menstrual cycles, it can affect between 2% to 5% of postmenopausal women.<sup>2</sup> Postmenopausal endometriosis generally believed to occur in women that are on hormone therapy or with a history of it. However, endometriosis may occur in postmenopausal women who had never used hormone therapy.<sup>3</sup> The data on postmenopausal disease is currently limited and the mechanism by which these lesions might develop during the postmenopausal years is unclear.<sup>4</sup>

<sup>1</sup> Balıkesir University School of Medicine Department of Obstetrics and Gynecology, Balıkesir

<sup>2</sup> Uzgoren Pathology Laboratory, Balıkesir

Address of Correspondence: Mine İslimye Taşkın  
Balıkesir University School of Medicine  
Department of Obstetrics and  
Gynecology Balıkesir, Turkey  
minetaskin1302@yahoo.com.tr

Submitted for Publication: 14. 05. 2014

Accepted for Publication: 13. 11. 2014

Here, we aimed to report a case of endometriosis in postmenopausal women with no history of hormone replacement therapy (HRT) use and history of endometriosis or infertility.

## Case Report

A 56 years old woman (gravida 3, para 3) was referred to our hospital with postmenopausal bleeding. The patient's menarche occurred when she was 12 years old and her menopause at 46. She had history of three vaginal births. Her past clinical history included hypertension. The patient had never used HRT. She had no familial or personal history of endometriosis. Her BMI was 33. A pelvic ultrasound scan revealed a right ovarian cystic mass of approximately 2.6x2.1cm in size and a left ovarian multiple lobulated hemorrhagic cystic mass approximately 5.0x2.8 cm in size (Figure 1A, B). Carcino-embryonic antigen (CEA), the cancer antigen 125 (CA 125), the cancer antigen 19-9 (CA19-9) and cancer antigen 15-3 (CA 15-3) levels were 2.56 U/mL, 31.31U/mL, 12.14U/mL, 26.37U/mL, respectively. The computed tomography scan showed multiple lobulated cystic masses at both adnexa. The patient was also submitted to bilateral breast ultrasound and bilateral mammography which showed no solid lesion. Endometrial biopsy was performed before surgery and histological examination of the biopsy revealed atrophic endometrium (Figure 2). Total abdominal hysterectomy and bi-

lateral salpingoophorectomy, and subsequent histological analysis revealed a left ovarian endometrioma. Microscopic analyses showed that the cystic mass was consisted of endometrial type epithelial cells, fibrous stroma and histiocytes loaded with hemosiderine (Figure 3A,B).

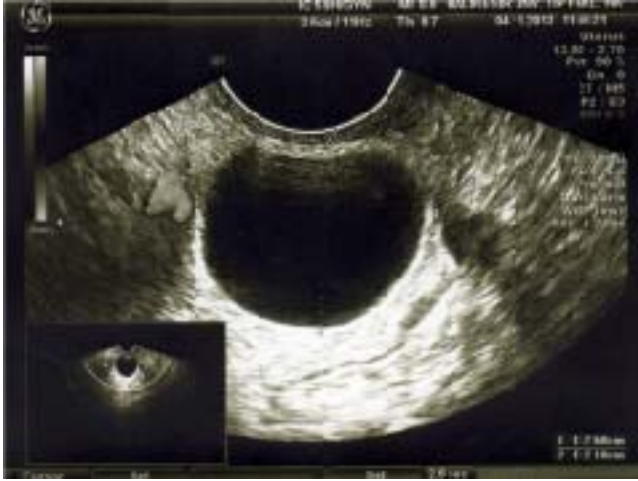

Figure 1A: Unilocular right ovarian cyst

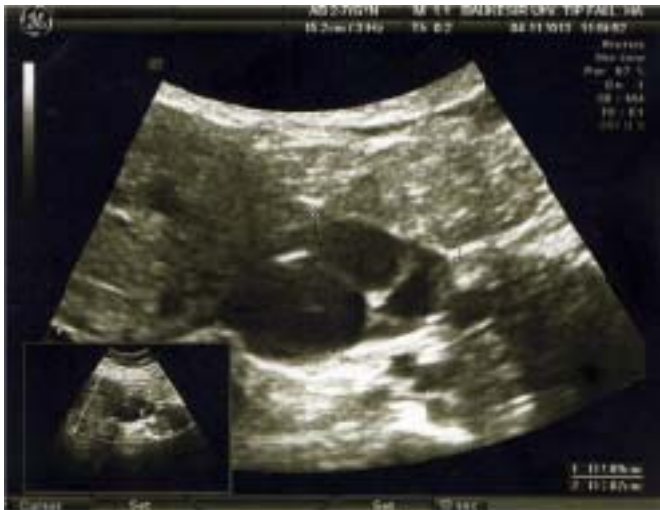

Figure 1B: Left ovarian multiple lobulated hemorrhagic cyst

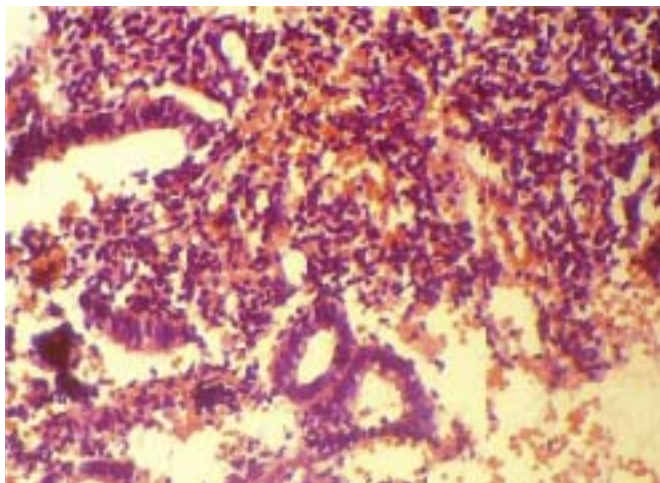


Figure 2: Atrophic endometrium in endometrial biopsy, x200, H&E

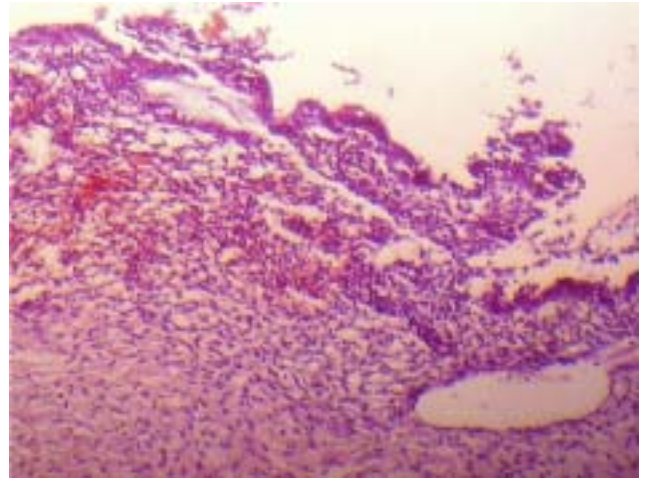


Figure 3A: Endometrial type epithelial cells in cyst wall, x200, H&E

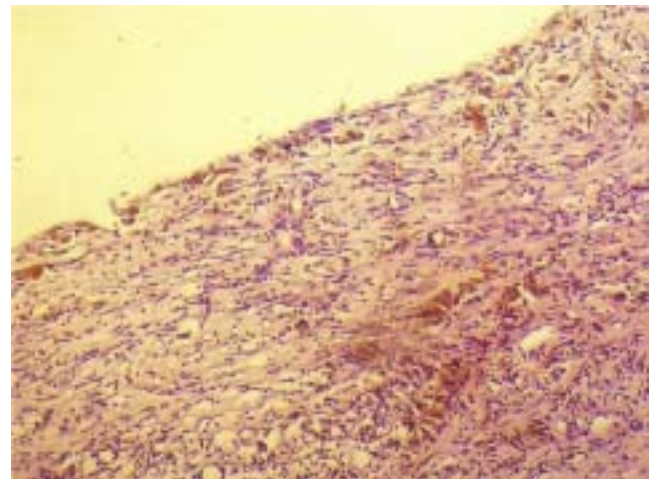


Figure 3B: Fibrous stroma and histiocytes loaded with hemosiderine, x200, H&E

Endometriosis is an estrogen dependent disease and there are several studies which associate postmenopausal endometriosis with HRT.<sup>1,5</sup> HRT is believed to stimulate the growth of endometriosis, especially with estrogen replacement therapy (ET); combined estrogen-progesterone therapy is also responsible.

This case supports that in postmenopausal period, endometriosis can appear for the first time without HRT, indicating complex pathogenic mechanisms. If endometriotic implants occur de novo in postmenopausal women in the absence of a functioning endometrium, it may be considered that these lesions develop as a result of alternative mechanisms. The first theory of postmenopausal endometriosis is coelomic metaplasia

Coelomic metaplasia hypothesis suggests that mesothelial cells of the ovary and peritoneal cavity may undergo metaplasia to form endometrial-like tissue.<sup>4</sup> This theory could only account for disease arising on the ovaries and peritoneal serosa. Oxholm and et al.<sup>6</sup> reported that postmenopausal endometriosis

sis was most located in ovaries. So this mechanism could explain the occurrence of postmenopausal endometriosis. The second theory of postmenopausal endometriosis is endometrial stem cells from vascular endometrial cell transportation. Endometriotic lesions primarily appear in areas that do not have contact with menstrual retrograde flow. Another possible mechanism is that these patients had previous undiagnosed endometriosis during reproductive period of their life.

Endometriosis is strictly a hormone dependent disease. Estrogen production during menopause may be resulted from extra ovarian sources such as the adrenal glands, the skin, the endometrial stroma, and the adipose tissue.<sup>7</sup> Local estrogen production from the adipose tissue due to obesity may be possible mechanism in growth of endometriosis.<sup>8</sup> In our case the patient was obese; so obesity might have contributed to high estrogen levels. Estrogen synthesis occurs via aromatization of androgens. High levels of aromatase enzyme activity have been demonstrated in cultured stromal cells derived from endometriotic lesions.<sup>9</sup> This local estrogen production leads progression of the disease, even in the absence of elevated serum estradiol levels. In the light of these data, due to local estrogen production and possible high aromatase activity in postmenopausal endometriosis; medical treatment with aromatase inhibitors may be a treatment of choice.<sup>7</sup>

Even if aromatase inhibitors are a treatment modality; first line treatment of postmenopausal endometriosis should be surgical because of the potential risk of malignancy. Kobayashi et al.<sup>10</sup> reported that ovarian endometriomas may develop ovarian cancer. Menopausal status, advancing age, endometrioma size being 9 cm or greater associated with significantly higher frequencies of development of ovarian cancer. They also concluded that clear cell carcinoma and endometrioid adenocarcinoma were commonly observed among these patients.

Conclusion: Adnexal masses in postmenopausal women are important because of the risk of malignancy and gynecologist must consider the possibility of ovarian tumor. Although there is a widely held belief that endometriosis is a disease of premenopausal women and cured by the menopause, endometriomas must be taken into consideration in differential diagnosis of postmenopausal adnexal masses as in our case.

## Hormon Replasman Öyküsü Olmayan Postmenopozal Hastada Endometriozis: Olgu Sunumu

### ÖZET

Endometriozis pelvik ağrı ve infertilite ile karakterize, benign, östrojen bağımlı, kronik bir hastalıktır. Pelvik endometriozisin prevalansı üreme çağındaki kadınlarda %6-10'dur. Endometriozis menstrüel siklusların varlığıyla ilişkilendirilse de postmenopozal hastaların %2-5'ini etkileyebilir. Bu sunumumuzla, postmenopozal endometriozis olgularına dikkat çekmek istedik.

56 yaşında kadın hasta postmenopozal vajinal kanama şikayeti ile başvurdu. 46 yaşında menopoza giren hastanın öyküsünde endometriozis, pelvik ağrı, hormon kullanımı mevcut değildi. Pelvik ultrasonografisinde 2,6x2,1 cm büyüklüğünde sağ overyan kistik kitle; 5x2,8 cm büyüklüğünde sol overyan multilobüle hemorajik kistik kitle saptandı. CA 125 düzeyi normal sınırlar içerisindeydi. Hastanın BT'sinde her iki adnekte multilobüle kistik kitleler izlendi. Total abdominal histerektomi ve bilateral salpingooferektomi yapıldı. Histopatolojik değerlendirme sonrası overyan endometriozis saptandı.

Endometriozis hormon replasman tedavisi öyküsü olmayan postmenopozal hastalarda da görülebilir. Bu nedenle postmenopozal adneksiyal kitlelerin ayırıcı tanısında endometriozis de akla gelmelidir.

**Anahtar Kelimeler:** Menopoz, Endometriozis, Overyan kist

### References

1. Goumenou AG, Chow C, Taylor A, Magos A. Endometriosis arising during oestrogen and testosterone treatment 17 years after abdominal hysterectomy: A case report. *Maturitas* 2003;46:239-41.
2. Punnonen R, Klemi PJ, Nikkanen V. Postmenopausal endometriosis. *Eur J Obstet Gynecol Reprod Biol* 1980; 11(3):195-200.
3. Manero MG, Royo P, Olartecoechea B, Alcázar JL. Endometriosis in a postmenopausal woman without previous hormonal therapy: a case report. *J Med Case Rep* 2009,18;3:135.
4. Bendon CL, Becker CM. Potential mechanisms of postmenopausal endometriosis. *Maturitas* 2012;72(3):214-9.
5. Bellina JH, Schenck D. Large postmenopausal ovarian endometrioma. *Obstet Gynecol* 2000;96(5 Pt 2):846.
6. Oxholm D, Knudsen UB, Kryger-Baggesen N, Ravn P. Postmenopausal endometriosis. *Acta Obstet Gynecol Scand* 2007;86(10):1158-64.
7. Fatemi HM, Al-Turki HA, Papanikolaou EG, Kosmas L, De Sutter P, Devroey P. Successful treatment of an aggressive recurrent post-menopausal endometriosis with an aromatase inhibitor. *Reprod Biomed Online* 2005,11:455-7.
8. Rosa-e-Silva JC, Carvalho BR, Barbosa Hde F, et al. Endometriosis in postmenopausal women without previous hormonal therapy: report of three cases. *Climateric* 2008;11:525-8.
9. Noble LS, Takayama K, Zeitoun KM, et al. Prostaglandin E2 stimulates aromatase expression in endometriosis-derived stromal cells. *The Journal of Clinical Endocrinology and Metabolism* 1997;82:600-6.
10. Kobayashi H, Sumimoto K, Kitanaka T, et al. Ovarian endometrioma--risks factors of ovarian cancer development. *Eur J Obstet Gynecol Reprod Biol* 2008;138:187-193.